

# Analysis of Diseases Due to Diabetes in Retinal Image by Detecting Macula and Exudates

Gargi Kashyap<sup>1</sup> and Debashree Dutta<sup>2</sup>

<sup>1</sup>GIMT, Guwahati, Assam

<sup>2</sup>M.Tech, ADBU Guwahati, Assam

E-mail: <sup>1</sup>[gargikashyap18@gmail.com](mailto:gargikashyap18@gmail.com), <sup>2</sup>[dutta.debashree02@gmail.com](mailto:dutta.debashree02@gmail.com)

---

**Abstract**—In this fast and furious era ubiquitous computing is growing so extensively and every manual works are shifting towards computerized work. People do not want to invest their time in processing, they just want to give an input and take an output immediately. And by the help of machines we can reduce the processing time. The main objective of this project "Analysis of Diseases due to Diabetes in Retinal Image by Detecting Macula and Exudates " is to design a system by digitally processing a retinal image clicked by a special type of camera known as Fundus camera to detect the macula present in the particular retinal image and to detect the exudates which is caused in the eyes of people acquiring diabetes.

Retina is a light sensitive layer of tissue, lining the inner surface of the eye. The optics of the eye creates an image of the visual world on the retina which serves much as the same function as the film in a camera. There are many inherited and acquired diseases or disorders like Maculopathy, Diabetic Retinopathy that may affect the retina. So, we have designed a system to detect the affected retinal images with our proposed methods like morphology and watershed operations in a simpler and time saving way which will be a help to the ophthalmologists in detecting diseases in a faster way compared to the traditional methods. The proposed method shows an efficiency of 85% in detecting exudates from various databases like STARE and local eye hospital.

**Keywords:** Macula, Exudates, Diabetic Retinopathy (DR), mathematical morphology, watershed.

## 1. INTRODUCTION

Medical imaging plays a very noteworthy role in medical informatics. Fundus retinal images play an important role in detecting various diseases. It also helps in classifying based on the symptoms. With the rapid evolution of technology, people are becoming even more and more electronically connected and as a result the ability to detect the abnormalities in the retinal images is becoming easier and simpler.

The detection of diseases like maculopathy, diabetic retinopathy etc by Ophthalmologists is very expensive and it takes much longer time. But with the advancement of image processing, retinal images can be processed for detecting various clinical components and any abnormalities, if present.

The advantages of the new approach over the traditional one are that

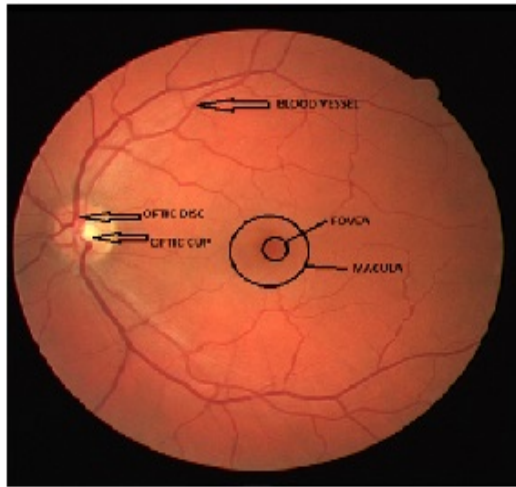
- i. It is simple and cheaper.
- ii. It is fast and time saving.

People having diabetes for very long time are prone to diseases like Diabetes retinopathy (DR). It is an eye disease which causes poor vision. If the disease is detected in the early stages then treatment can be taken to slow down the progression but it is difficult to detect early stage of DR, such it has no early warning signs. DR damages the blood vessels and macula and formation of exudates happens in the retinal image. Hence early detection of abnormality in macula and detection of exudates will help the patients in taking the right treatment as soon as possible. The clinical components of retinal images are fovea, macula, optic disc, optic cup and blood vessels as shown in Fig. 1. The macula is an oval-shaped highly pigmented yellow spot near the center of the retina of the human eye and fovea is the central part of macula. It is responsible for the central sharp vision. Hence, detection of macula is very important in diabetes. Any abnormality in the macula may lead to loss of central vision. Exudates are one of the earliest and most prevalent symptoms of diseases leading to blindness in diabetic retinopathy and wet macular degeneration. It is bright lipids and proteins leaked from the blood vessels. Hence, detection of exudates is an important diagnostic task for preventing blindness in diabetic patients.

In the paper [1], an efficient algorithm is presented to detect the bright lesions (exudates) in the retinal images. Color channels and some image features like intensity gradients and image texture are used to separate exudates from physiological features in the retinal images. The proposed method is applied on many databases and it shows promising result.

In [2], adaptive thresholding and classification is done to detect the exudates in the retinal images. Adaptive thresholding is performed in two steps, one is region based segmentation and other is morphological gradient technique. Classification is done by rule base classification. In this paper [3], detection of exudates is performed by dividing the image

into 64 sub-images followed by region growing and edge detection. In [4], optic disc and exudates are detected by watershed segmentation, average filtering and contrast adjustment. In [5], k means clustering and mathematical morphology methods are used to detect exudates in the retinal images.



**Fig. 1: The clinical components of retinal image**

In the proposed work, the macula and exudates are detected in the retinal images collected from various databases like STARE and local eye hospitals using various methods like mathematical morphology and watershed operations. The rest of the paper is organized as follows. In Section II, the techniques used in the proposed algorithm are explained. In Section III, experimental results of the algorithm are discussed. Finally, the conclusion of the paper is presented in Section IV.

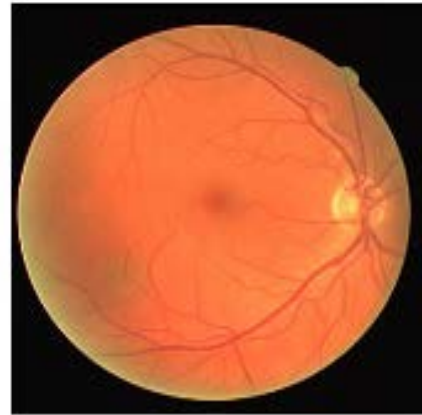## 2. PROPOSED METHODOLOGY

The overall proposed system consists of two parts;

First is detection of macula in the retinal image using mathematical morphology and second is detection of exudates in the retinal image using mathematical morphology and watershed algorithm.

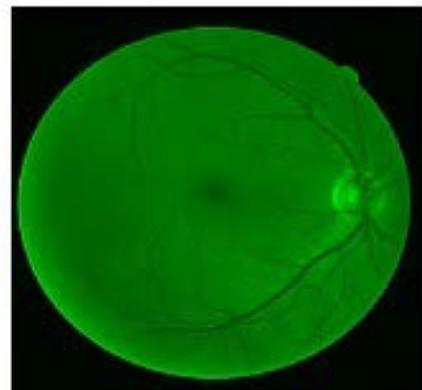
### 2.1 Detection of Macula

The detection of Macula in fundus retinal image is an important part. In manual analysis, due to unavailability of trained ophthalmologists, the diagnosis of retinal diseases becomes difficult. Thus the proposed method demonstrates an approach to the rapid detection and extraction of the macula and exudates from the human retinal image with the help of MATLAB. The retinal images are taken from the STARE database and local eye hospital, which are given as an input to the system. The original retinal image collected from local eye hospital is shown in Fig. 2.

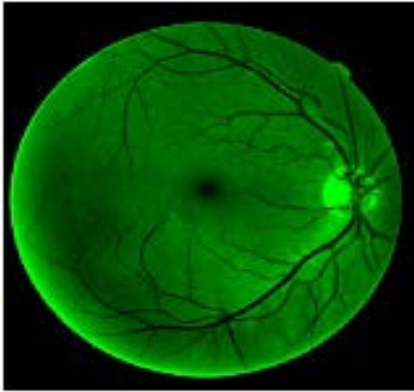


**Fig. 2: The original retinal image collected from local eye hospital**

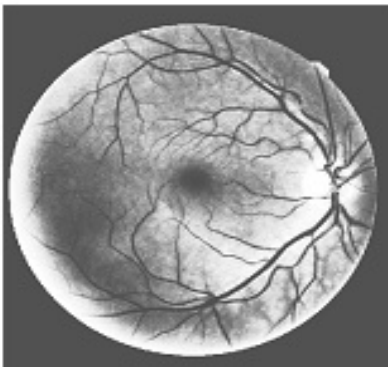
For the detection of macula, various color models like RGB, YCbCr and HSV models are implemented upon the retinal image separately. The color model implementations is performed in all the retinal images, in which the green plane image resulting from the RGB model gives a clear view of the macula and some other components too. So, the RGB model is selected and the other two models are avoided. Even if the RGB model is selected, only the green plane is desirable and so the blue and red planes are also avoided. The resulting green plane image is contrasted and enhanced to make the components more visible and clear. Fig. 3 shows the green plane retinal image and Fig. 4 shows the enhanced retinal image. Upon the enhanced green image Histogram Equalization is performed. Fig. 5 shows the equalized retinal image. Then bit plane slicing is performed on the equalized retinal image. The plane is sliced into many planes. The plane having the necessary information is taken for further processing and discarding the other planes. Bit plane slicing represents an image in terms of pixels digitally. These pixels are then expressed in terms of logical bits. Fig. 6 shows the retinal image upon which bit plane slicing is performed.



**Fig. 3: The green plane of the retinal image**



**Fig. 4: The enhanced retinal image**




**Fig. 5: The equalized retinal image**



**Fig. 6: The bit plane sliced retinal image**

After the Bit plane slicing, the sliced retinal image is exposed to the mathematical morphological operations. During the morphological operations, the image is opened, closed, dilated and eroded, by selecting a particular structural element which may be a square, rectangle, disk, diamond, hexagon, etc of any size depending on the retinal image respectively. The structural element helps in reducing the other visible components like blood vessels and extracting out only the macula from the centre of the retinal image. Finally, the macula is almost extracted out from the retinal image.

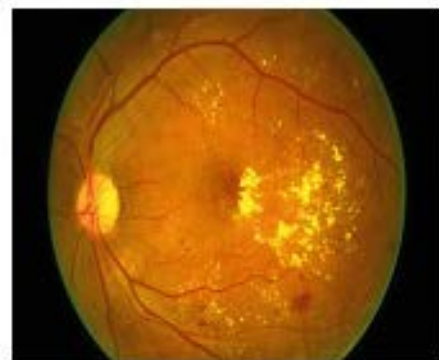Fig. 7 shows the macula after mathematical morphological operations.



**Fig. 7: The detected macula after mathematical morphology**

## 2.2 Detection of Exudates

For the detection of exudates, the retinal image collected from local eye hospital is first converted into gray scale image to make the exudates more visible, as in gray scale the image intensities are equalized between shades of black and white. Fig. 8 shows the original retinal image collected from local eye hospital having exudates and Fig. 9 shows the grey scale retinal image. The optic disc appears to be brighter than the exudates as optic disc is the brightest part of the retina. Then histogram equalization and edge detection are carried out which makes it clear that the intensity at the left most part or right most part is the highest, which is the position of the optic disc and is not exudates. Now, the grayscale image is equalized using Histogram Equalization and then the plane is sliced into many planes with the help of bit plane slicing. The image is sliced into bits where the information of the exudates is obtained in one of the bit plane. Then mathematical morphology operation such as closing operation is performed upon the sliced image, followed by dilation and erosion. Upon the eroded image watershed operation is performed and finally exudates are detected. Fig. 10 shows the bit plane sliced retinal image, Fig. 11 shows the eroded retinal image and Fig. 12 shows the detected exudates using watershed algorithm.



**Fig. 8: The original retinal images collected from local eye hospital having exudates**

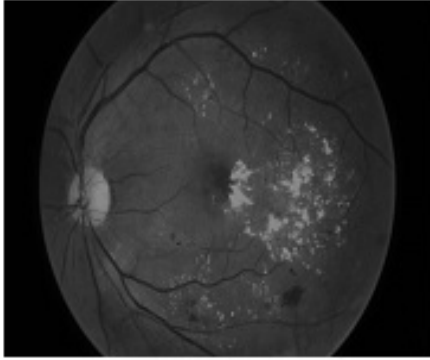


Fig. 9: The gray scale retinal images




Fig. 20: The bit plane sliced retinal images.

In order to determine the effectiveness of our proposed method on the retinal images, 35 numbers of retinal images are used. Two databases of retinal images such as STARE and local eye hospital are utilized in this paper. The presence of exudates in these images are also approved by an expert of a local eye hospital, so it can be considered as an efficient approach for the detection of exudates in retinal images which will further help in analysis of diabetic diseases. The proposed method efficiently detects the macula and exudates from images of different databases as shown in Table 1. Here it shows an accuracy of 85% in extracting the macula and exudates from different databases.




Fig. 31: The eroded retinal image

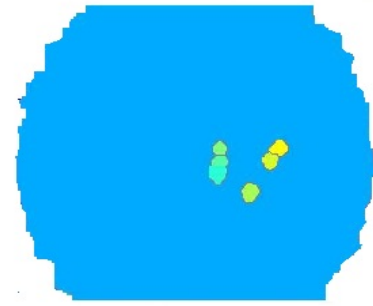


Fig. 42: The detected exudates after using watershed algorithm

DATABASE	TESTED IMAGES	DETECTED IMAGES	ACCURACY
LOCAL EYE HOSPITAL	30	25	85%
STARE	5	3	

Table 5: The accuracy of the system in detecting macula and exudates

### 3. CONCLUSION

In this paper, a novel method for analysis of diseases due to diabetes in the retinal image by detecting macula and exudates is presented. For detecting macula and exudates various methods have been developed based on image processing, mathematical morphology and watershed algorithm. The result of this method is very

promising and detects the macula and the exudates efficiently in 28 retinal images out of 35 retinal images. The presence of exudates in these images are also approved by an expert of a local eye hospital, so it can be considered as an efficient approach for the detection of exudates and macula in retinal images which will further help in analysis of diabetic diseases.

### REFERENCES

- [1] Abbadi, K.El. N., and Saadi, E., "Automatic Detection Of Exudates in Retinal Images", *IJCSI International Journal Of Computer Science* , Vol 10, Issue No 2, No 1 , March 2013, ISSN- (online) 1694-0784.
- [2] Jaafar, F. H., Nandi, K. A., and Nuaimy, W., "Detection of Exudates From Digital Fundus Images Using a Region Based Segmentation Technique", in *Proceedings 19th European Signal Processing Conference (EUSIPCO 2011)* , Barcelona, Spain, August 29-September 2, 2011.
- [3] Li, H., and Chutatape, O., "Automated feature extraction in color retinal images by a model based approach", *IEEE Trans. on Medical Engineering*, vol.51, pp.246-254, 2004.

- [4] Reza, W.A., Eswaran, C., and Dimiyati, K., "Diagnosis of Diabetic Retinopathy: Automatic Extraction of Optic Disc and Exudates from Retinal Images Using Marker- controlled Watershed Transformation ", *Springer, J Med.Syst.*,online Jan 2010.
- [5] Amel, F.,Mohammed,M. and Abdelhafid, B., "Improvement of the Hard Exudates Detection Method Used For Computer-Aided Diagnosis of Diabetic Retinopathy", in *I.J.Image,Graphics and Signal Processing(ijigsp.2012.04.03)*,2 May 2012, pp. 19-27.